

CELL VOLUME OF NEOCORTICAL NEURONS FROM PATIENTS WITH ALZHEIMER'S DISEASE

Mads J. Bundgaard¹, Lisbeth Regeur¹, Juan Troncoso², Mark J. West³, Bente Pakkenberg¹

¹Neurological Research Laboratory, Bartholin Institutttet, Kommunehospitalet, 1399 Copenhagen K, Denmark

²Johns Hopkins University Hospital, Baltimore, U.S.A.

³Stereological Research Laboratory, University of Aarhus, 8000 Århus C, Denmark

ABSTRACT

The unbiased estimation of total neuron number in neocortices of five patients, age range 79 to 88 yrs with Alzheimer's disease was compared with total neocortical neuron number in four non-demented controls, age range 70 to 101 yrs. The demented patients were from a longitudinal study on Alzheimer's disease from Johns Hopkins University Hospital (JHUH) in Baltimore, USA. The total nerve cell number in the Alzheimer group was $19.7 \cdot 10^9$ with a coefficient of variation (CV) = 0.17, while total neuron number in the control group was $18.6 \cdot 10^9$, CV = 0.08, the difference of 6 percent is obviously not significant.

Each sampled neocortical neuron was measured in a semiautomatic procedure using the menu-driven computer program CAST-GRID (Olympus, Denmark). The rotator, the unbiased stereological principle by which an estimate of the volume of an object can be obtained by rotating a 3-D object around an axis in the plane, was used to obtain a unbiased estimate of the mean cell volume and size distribution of neocortical neurons.

We found a statistically significant increase in the size of the neuronal nuclei in neocortices from patients with Alzheimer's disease from JHUH: $351 \mu\text{m}^3$ (CV = 0.07) vs. $287 \mu\text{m}^3$ (CV = 0.17), an increase of 22% over Danish controls, $2p = 0.047$, whereas the five percent increase in neuron perikaryon volume from $1146 \mu\text{m}^3$ (CV = 0.11) in controls to $1197 \mu\text{m}^3$ (CV = 0.13) in the Alzheimer cases was not statistically significant.

Keywords: Alzheimer, neocortex, neurostereology, rotator, sizedistribution, volume

INTRODUCTION

Alzheimer's disease (AD) is a chronic progressive neurodegenerative disorder clinically characterized by an acquired global affection of intellect, memory and personality (Bolwig TG 1994). It is the most common course of dementia in the elderly, accounting for more than half of the cases. The diagnosis is confirmed histologically by the presence of neocortical amyloid plaques containing dystrophic neurites, neurofibrillary tangles and paired helical filaments. On gross examination an atrophy can be seen, especially targeting the frontal and hippocampal cortex (Katzman R et al; Vogel FS et al. 1994), the same areas where the histopathological features are most pronounced (Selkoe DJ).

In contrast to Parkinson's disease, primarily affecting the dopaminergic neurons, AD involves multiple neurotransmitter systems. The greatest deficit is in the cholinergic system, but most plaques contain neurites of various transmitter specificities (Katzman R et al; Selkoe DJ).

Several investigations of cortical neuron content and size have been made (Terry RD et al. 1987; Mann DMA et al. 1985; Davies CA et al. 1987; Terry RD et al. 1981; Hansen LA et al. 1988; Hubbard BM et al. 1985; Vogt BA et al. 1990; Regeur L et al. 1994). However, the only study using unbiased stereological methods found no neuron loss in the neocortex of patients suffering AD (Regeur L et al. 1994). The previous investigations on neuronal size in neocortices from Alzheimer patients have all been done with potentially biased methods.

The aim of the present study was to estimate the cortical neuronal size distribution in controls and AD patients using unbiased stereological methods and to test whether the neocortical neurons in AD patients have the same size as in controls.

MATERIALS

From a longitudinal study on AD at Johns Hopkins University Hospital, USA, five brains, three males and two females, aged 79 to 88, were sampled consecutively. Four brains, two males and two females, from nondemented neurologically sound individuals with the same age range (70 to 101 years) were selected from a larger brain repository in Denmark. All four Alzheimer brains and one control came from Baltimore, while the remaining four controls were from Denmark. The brains in the repository are prospectively collected for the purpose of stereological investigations, and none of the control brains had any AD-pathology. The diagnosis of AD were made at JHUP on clinical records and histopathological examination.

METHOD

The brains were removed from the patients within 5 hours, fixed in 0.1M sodium phosphate buffered formaldehyde (pH 7.2, 4% formaldehyde) for at least 5 months. The meninges were removed, and the cerebellum and brainstem detached at the level of the third cranial nerve. Right or left hemisphere were chosen at random. The frontal-, temporal-, parietal- and occipital regions were delineated and painted on the pial surface in different colours as described elsewhere (Braendgaard H et al. 1990). The hemisphere were embedded in 6% agar, sliced coronally at 7 mm intervals and the neocortical volume estimated by the Cavalieri's principle. A total of about 250 points was counted on the neocortical sectional areas providing a coefficient of error ($CE=SEM/mean$) on the estimates of total volume of 6-8%. From every second slice, starting randomly, transcortical wedges were sampled uniformly and systematically from each neocortical region. Each wedge was cut into 2-mm-wide parallel bars, providing 25-50 bars per region. These were subsampled uniformly so that each region was represented by 7 to 12 bars and each brain by 31-44 bars. Each bar was rotated randomly around their vertical axis and plastic embedded in LKB-historesin®. One 35 µm thick section was cut from each bar, stained with a modified Wolbach's Giemsa stain and used for counting in optical dissectors. Each sampled neuron was then volume estimated by the rotator method (Jensen EBV et al. 1993) using the CAST-GRID® computer program (Olympus, Denmark).

All sections were coded when examined. The optical disector equipment consists of a BH-2 Olympus microscope with motorized XY-stage, and an electronic microcator with digital readout for measuring movements in the Z-direction. High image resolution and a thin focal plane were obtained using a high numerical aperture (NA 1.4) and an 100x oil-immersion

objective for cell-counting and volume estimation. Using the CAST-GRID program and an Amiga 2000 computer, a counting frame was superimposed on a colour monitor where manual counting took place.

An unbiased estimate of the total number of neurons in each neocortical region of the hemisphere, $N(\text{neu,reg})$, was calculated by multiplying the Cavalieri-estimate of the regional neocortical reference volume, $V(\text{reg})$, by the regional numerical density, $N_v(\text{neu/reg})$, according to eq.(1)

$$N(\text{neu,reg}) = N_v(\text{neu/reg}) \times V(\text{reg}) = (\Sigma Q' / \Sigma v(\text{dis})) \times V(\text{reg}) \tag{1}$$

where $\Sigma Q'$ is the total number of neurons counted in all disectors in a region, and $\Sigma v(\text{dis})$ is the total volume of these disectors equal to the area of the test frame (in this case 400 cm^2 corrected by the linear magnification 3464), multiplied by the height of the disector ($15 \mu\text{m}$) and by their total number.

On average, a total of $\Sigma Q' = 408$ neurons was counted and volume estimated in an average of 200 disectors. The final estimate of total neuron number had a CE of 8,9%. Changes in the tissue volume between the Cavalieri volume estimate and the numerical density/rotator volume estimate were quantified and the tissue was found to swell 9.4%, with no difference between the groups. The results are not corrected for this swelling.

RESULTS

The size distribution of neocortical neurons and their nuclei is found to be unimodal and rightskewed in AD patients and controls. The enlargement of nuclei affects all sizes of neurons as seen in Fig. 1.

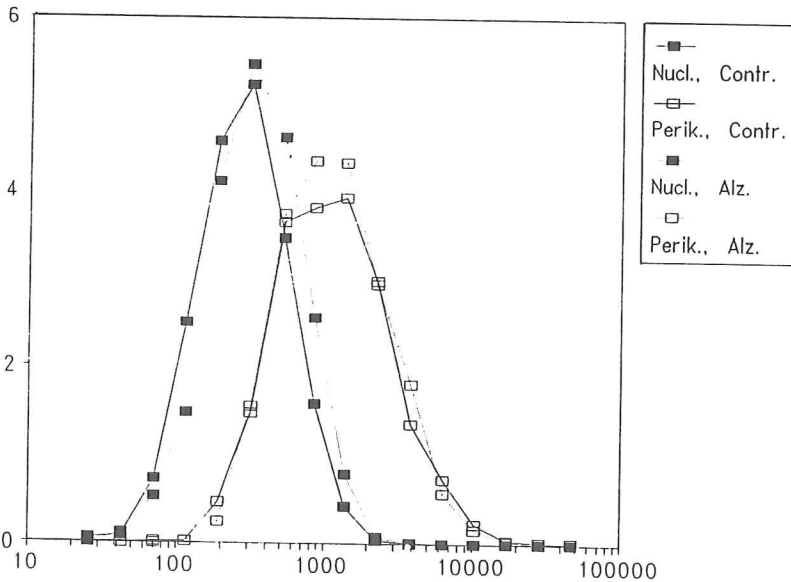


Fig.1. Size distribution of neocortical neurons for controls and Alzheimer patients is shown on a logarithmic scale (μm^3) on the ordinate and number of neurons (10^9) on the abscissa.

A significant increase in neocortical neuronal nuclei size was found with a normal neocortical neuron number. As can be seen in Table 1 and 2, there is no significant difference in the volume of perikaryon or nuclei in one particular region; however, the nuclei have a tendency to be bigger in AD patients. When all regions of neocortex is added up as seen in Table 3 the nuclei have enlarged from $287 \mu\text{m}^3$ (CV=0.17) in control cases to $351 \mu\text{m}^3$ (CV=0.07) in Alzheimer patients, which is statistically significant ($2p=0.047$). A small neuronal loss in one region could be overlooked but as seen in Table 1 and 2 the neuronal content in the regions is the same in AD patients as in controls. The total neocortical neuron number is seen in Table 3, namely $19.7 \cdot 10^9$ (CV=0.17) neurons in AD patients vs. $18.6 \cdot 10^9$ (CV=0.08) neocortical neurons in control cases, clearly not a significant difference ($2p=0.54$).

The volume of the white matter in the brain is not altered in AD patients (352.2 cm^3 (CV=0.23) in controls vs. 363.6 (CV=0.26) in AD patients, $2p=0.85$). A tendency to a decrease in grey matter in AD patients is found (from 45.3 cm^3 (CV=0.12) in controls to 39.6 cm^3 (CV=0.16) in AD patients, $2p=0.19$). In Table 4 is also shown a highly significant ($2p=0.01$) enlargement of the ventricles in AD patients, namely from 24.5 cm^3 (CV=0.44) to 65.2 cm^3 (CV=0.35).

Table 1 and 2: Volume of neuronal nuclei (V_{nucl}), volume of neuronal perikaryon (V_{peri}) in μm^3 , and number of neurons (10^9) in the frontal (front), temporal (temp), parietal (par) and occipital (occ) region of the neocortex of Alzheimer patients (AD) and controls (c). CV = SD/mean is given in parenthesis.

Table 1	Front _{AD}	Front _c	2p	Temp _{AD}	Temp _c	2p
V_{nucl} (μm^3)	319.2 (0.20)	393.1 (0.11)	0.09	323.1 (0.21)	397.2 (0.10)	0.10
V_{peri} (μm^3)	1307 (0.15)	1384 (0.17)	0.60	1324 (0.18)	1368 (0.23)	0.82
Neuron number (10^9)	6.5 (0.13)	7.6 (0.15)	0.14	3.4 (0.10)	3.5 (0.29)	0.93

Table 2	Par _{AD}	Par _c	2p	Occ _{AD}	Occ _c	2p
V_{nucl} (μm^3)	287.7 (0.17)	353.4 (0.15)	0.09	207 (0.09)	251.8 (0.17)	0.08
V_{peri} (μm^3)	1079 (0.11)	1155 (0.16)	0.46	786 (0.05)	807 (0.17)	0.76
Neuron number (10^9)	4.7 (0.21)	3.9 (0.11)	0.21	4.0 (0.23)	4.7 (0.34)	0.46

Table 3: The volume of neuronal nuclei (V_{nucl}), volume of neuronal perikaryon (V_{peri}) in μm^3 , and number of neurons (10^9) in neocortex of Alzheimer patients (AD) and controls (c). CV = SD/mean is given in parenthesis.

Table 3	total cortex _{AD}	total cortex _c	2p
V_{nucl} (μm^3)	351 (0.07)	287 (0.17)	0.047 *
V_{peri} (μm^3)	1197 (0.13)	1146 (0.11)	0.60
Neuron number (10^9)	19.7 (0.17)	18.6 (0.08)	0.54

Table 4: The volume of white matter, grey matter and ventricles (cm^3) in Alzheimer patients and controls.

Table 4	Alzheimer	Controls	2p
$V_{\text{White matter}}$ (cm^3)	363.3 (0.26)	352.2 (0.23)	0.85
$V_{\text{Grey matter}}$ (cm^3)	39.6 (0.16)	45.3 (0.12)	0.19
$V_{\text{ventricle}}$ (cm^3)	65.2 (0.35)	24.5 (0.44)	0.01 *

DISCUSSION

The present study showed no difference in neuronal perikaryon volume between the neurons in the AD brains and normal controls. However, a significant increase was seen in nuclei volume.

Since all AD brains and only one control came from JHUH and the rest of the controls came from Denmark, the results could be caused by a difference in size due to difference in fixation procedure. Confirmation of the results therefore awaits further studies on more brains from JHUH and Denmark in each group.

The rotator method provides time efficient unbiased estimates of volume of neurons from the neocortex. Rotating the tissue makes it impossible to distinguish between different layers and subpopulations of neurons in the neocortex unbiasedly.

Since the size distribution of nuclei is displaced to the right, either all neuronal nuclei or a specific subgroup of neurons having a size distribution identical to the rest of the neocortical neurons must have enlarged. The subgroup of neurons could be of a specific neurotransmitter variety or innervated by a specific region. It is not possible that the change in nuclei size only affects a certain sizeclass of neurons as often postulated (Davies CA et al. 1987; Vogt BA et al. 1990; Hansen LA et al. 1988; Terry RD et al. 1981; Mann DMA et al. 1985).

This study confirms that neocortical neuronal loss is not found in the AD brains.

ACKNOWLEDGEMENTS

We acknowledge the financial support by Direktør Emil Hertz and wife Inger Hertz' Foundation, the Ferd. and Ellen Hindsgaul Foundation, The Hartmann Brothers Foundation and Jubilæumsfonden af 1963.

REFERENCES

- Braendgaard H, Evans SM, Howard CV, Gundersen HJG. The total number of neurons in the human neocortex unbiasedly estimated using optical disectors. *J Microsc* 1990; 157: 285-304
- Bolwig TG. Demens-kronisk organisk psykosyndrom. In: Hemmingsen R, Parnas J, Sørensen T, Gjerris A, Bolwig TG, Reisby N, *Klinisk psykiatri* 1st ed. ch. 10. Copenhagen: Munksgaard 1994: 225-254
- Davies CA, Mann DMA, Sumpter PQ, Yates PO. A quantitative morphometric analysis of the neuronal and synaptic content of the frontal and temporal cortex in patients with Alzheimer's disease. *J Neu Sci* 1987; 78: 151-164
- Hansen LA, Deteresa R, Davies P, Terry RD. Neocortical morphometry, lesion counts, and choline acetyltransferase levels in the age spectrum of Alzheimer's disease. *Neurology* 1988; 38: 48-54
- Hubbard BM, Anderson JM. Age-related variations in the neuron content of the cerebral cortex in senile dementia of Alzheimer type. *Neuropath Appl Neurobiol* 1985; 11: 369-382
- Jensen EBV, Gundersen HJG. The rotator. *J Microsc* 1993; 170; 1: 35-44
- Katzman R, Thal LJ. Neurochemistry of Alzheimer's disease. In: Siegel GJ, *Basic Neurochemistry: molecular, cellular and medical aspects* 4th ed. ch. 43. New York: Raven Press 1989: 827-838
- Mann DMA, Yates PO, Marcyniuk B. Some morphometric observations on the cerebral cortex and hippocampus in presenile Alzheimer's disease, senile dementia of Alzheimer type and Down's syndrome in middle age. *J Neu Sci* 1985;69: 139-159
- Regeur L, Jensen GB, Pakkenberg H, Evans SM, Pakkenberg B. No global neocortical nerve cell loss in brains from patients with senile dementia of Alzheimer's type. *Neurobiol Aging* 1994; 15; 3: 347-352
- Selkoe DJ. The molecular pathology of Alzheimer's disease. *Neuron* 1991; 6: 487-498
- Selkoe DJ. Amyloid protein and Alzheimer's disease. *Sci American* 1991; nov: 40-47
- Terry RD, DeTeresa R, Hansen LA. Neocortical cell counts in normal adult aging. *Ann Neurol* 1987; 21; 6:530-539
- Terry RD, Peck A, Deteresa R, Schechter R, Horoupian DS. Some Morphometric aspects of the brain in senile dementia of the Alzheimer type. *Ann Neurol* 1981; 10: 184-192
- Vogel FS, Bouldin TW. The nervous system. In: Rubin E, Farber JL, *Pathology* 2nd ed. ch 28. Pennsylvania 1994: J.B. Lippincott Company: 1372-1456
- Vogt BA, Van Hoesen GW, Vogt LJ. Laminar Distribution of neuron degeneration in posterior cingulate cortex in Alzheimer's disease. *Acta Neuropath* 1990; 80: 581-589